

Case-1 50 year old female edentulous Patient wearing removable complete dentures since 12 years wished to have all fixed teeth on implants

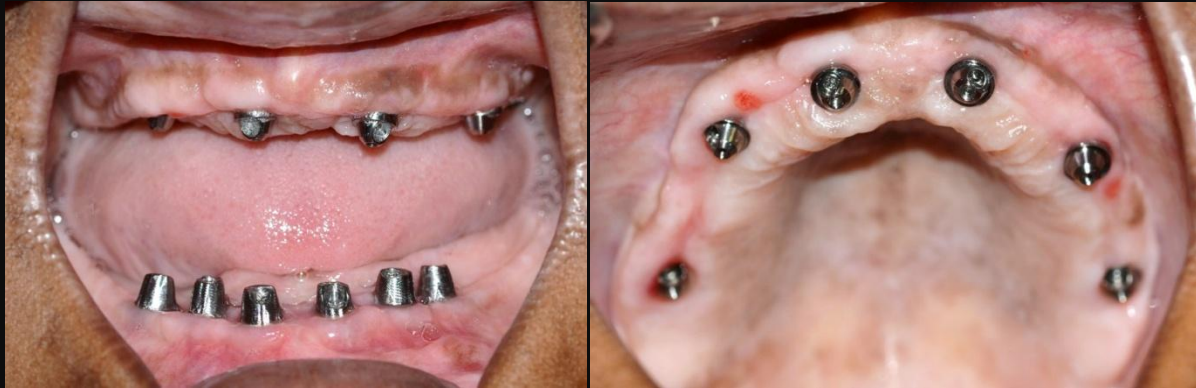

Fig.1-Implants in the Upper and lower jaws fig. 2- Upper implants before fixing teeth set

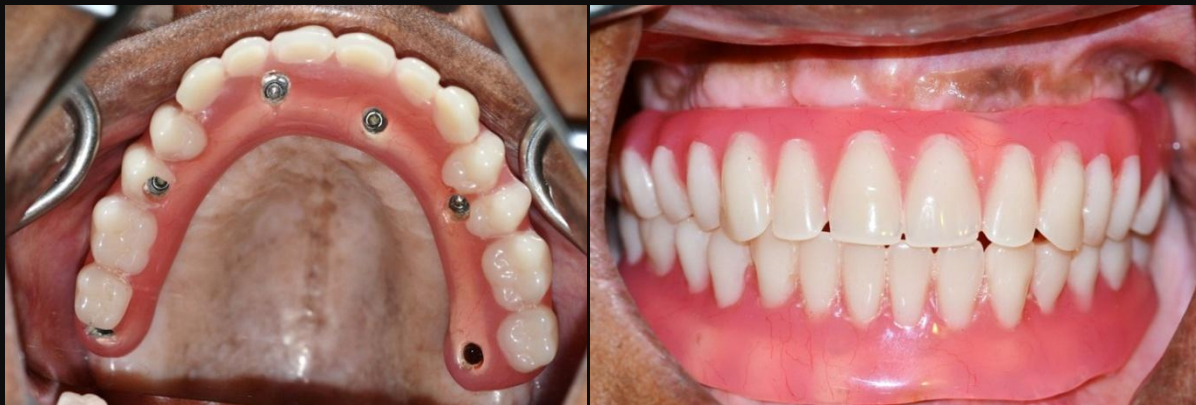

Fig.3-Upper teeth set fixed over the implants fig.4- Upper and lower teeth sets fixed over the implants

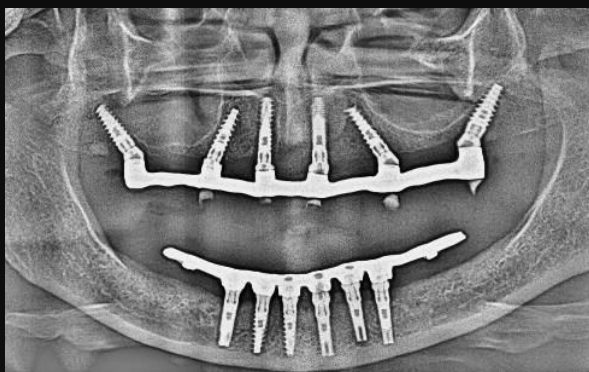


Fig.5- Radiograph after fixing the teeth over the implants showing all on 6 techniques

Case-2 55 year old male patient presented with completely lost lower teeth (wearing denture) and few upper teeth which were mobile. Problems of esthetics and chewing efficiency. Could not move out without teeth.

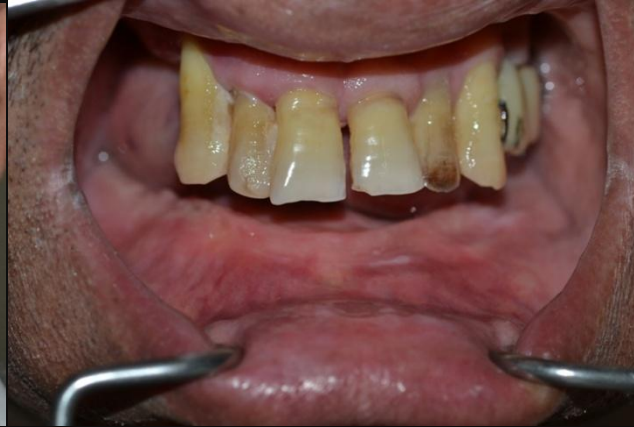
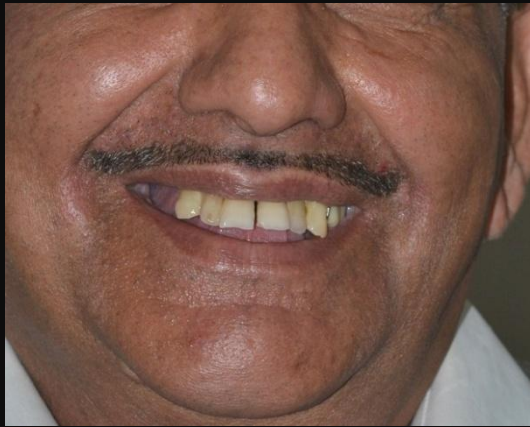
Fig.1 At the time of consultation, before the all on 4 procedure fig.2. Upper mobile teeth and lower all missing teeth

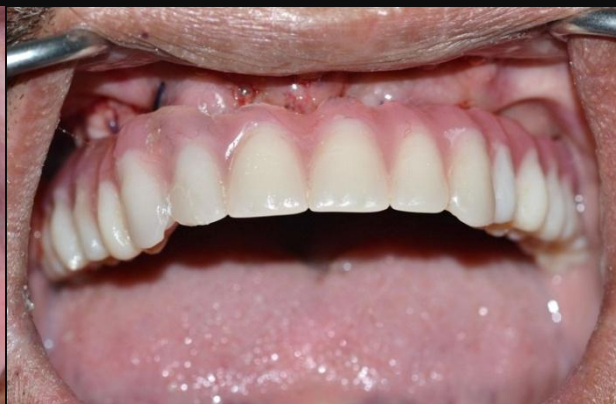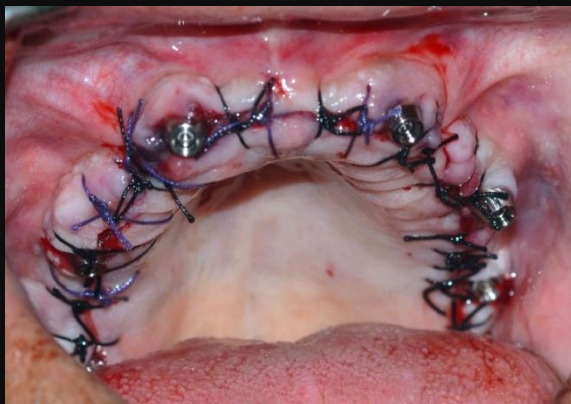


Fig.3-Upper teeth extracted and implants inserted fig.4. The prefabricated teeth set is fixed over the implants at the same day /same sitting.

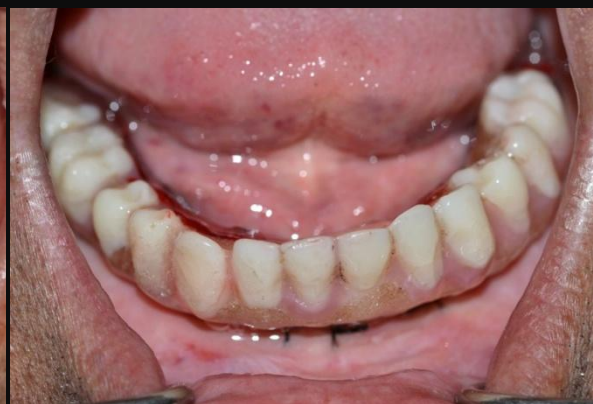
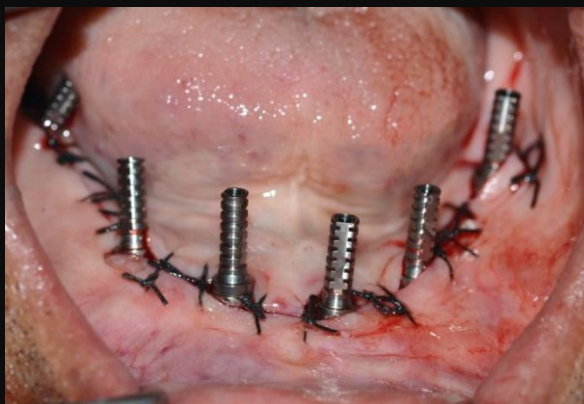
Fig.5-Lower implants inserted fig.6-Prefabricated teeth set is fixed over the implants at the same day /same sitting.

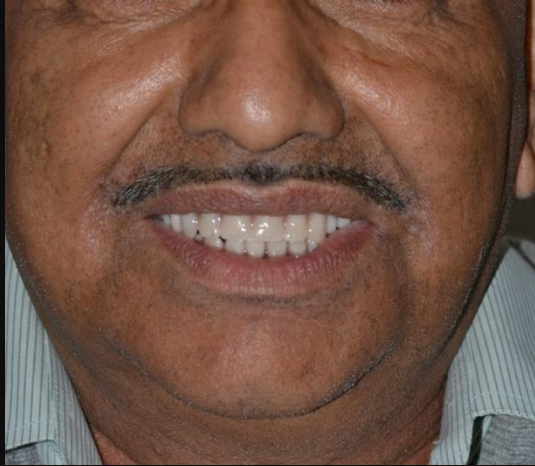

Fig.7- patient left the clinic with the upper and lower fixed teeth with all on 4 technique.